

# Risk of Mesh Extrusion and Other Mesh-Related Complications After Laparoscopic Sacral Colpopexy with or without Concurrent Laparoscopic-Assisted Vaginal Hysterectomy: Experience of 402 Patients

Assia A. Stepanian, MD\*, John R. Miklos, MD, Robert D. Moore, DO, and T. Fleming Mattox, MD

*From the Center for Women's Care and Reproductive Surgery, Atlanta, GA (Dr. Stepanian); Atlanta Urogynecology Associates, Atlanta, GA (Drs. Miklos and Moore); and the Carolina Continence Center, Greenville, South Carolina (Dr. Mattox).*

**ABSTRACT** **Study Objective:** To estimate the incidence of mesh-related complications including mesh erosion/extrusion rates in patients undergoing laparoscopic sacral colpopexy, with or without concurrent hysterectomy, using macroporous soft polypropylene mesh. **Design:** Historical cohort study (Canadian Task Force classification II-2). **Setting:** Private urogynecology clinic. **Patients:** A total of 446 consecutive patients with uterovaginal or vaginal vault prolapse underwent laparoscopic sacral colpopexy with use of macroporous soft polypropylene mesh from January 2003 through January 2007. In all, 402 consecutive patients met enrollment criteria. Two groups of patients were identified: (1) those receiving concurrent hysterectomy ( $n = 130$ ); and (2) those with a history of hysterectomy ( $n = 272$ ). **Interventions:** Patients were treated with laparoscopic sacral colpopexy with use of macroporous soft polypropylene mesh in conjunction with other laparoscopic and/or vaginal procedures. **Measurements and Main Results:** Data were collected in the form of chart reviews and patient questionnaires. Comparisons were made between groups 1 and 2. Patient demographics, history, mesh erosion/extrusion rates, and mesh-related complications were analyzed. Length of follow-up was 1 to 54 months with a median follow-up time of 12 months. No statistically significant differences existed between 2 groups in rates of mesh erosion/extrusion or other mesh-related complications. Overall vaginal mesh erosion/extrusion rate was 1.2% (95% CI 0.5%–2.7%) with an associated mesh revision rate of 1.2% (95% CI 0.5%–2.7%). Patients with concurrent hysterectomy had an erosion/extrusion rate of 2.3% (3/130) as compared with 0.7% (2/272) in patients with a history of hysterectomy,  $p = .18$ . No cases of mesh erosion through organs and tissues other than vaginal mucosa were observed. Cuff abscess occurred in 1 patient with concurrent hysterectomy, with an overall infection rate of 0.3% (95% CI 0.01%–1.2%). One more patient developed an inflammatory reaction to the mesh. Excision of exposed mesh was performed in all 5 patients with mesh extrusion. Vaginal approach to excision was uniformly used. Laparoscopic removal of the entire mesh took place in 4 patients with persistent pelvic pain, in 1 patient with cuff abscess, and in one patient with a questionable mesh reaction. An estimated 975 to 17 000 patients were required in each group to achieve power to detect a statistically significant difference in rate of mesh-related complications in this study. **Conclusion:** Risk of mesh extrusion or other mesh-related complications after laparoscopic sacral colpopexy using soft macroporous Y-shaped polypropylene mesh is about 1% in our study. No significant increase in risk of mesh-related complications was observed in patients receiving concurrent hysterectomy when compared with patients who had a previous hysterectomy. The sample size of almost 2000 patients was needed to detect a statistically significant difference in rate of mesh-extrusion in this study. *Journal of Minimally Invasive Gynecology* (2008) 15, 188–196 © 2008 AAGL. All rights reserved.

**Keywords:** Laparoscopy; Sacral colpopexy; Mesh erosion; Mesh extrusion; Infection; Hysterectomy; Mesh; Uterovaginal prolapse; Pelvic organ prolapse; Pelvic floor relaxation; Vaginal vault prolapse

---

The authors have no commercial, proprietary, or financial interest in the products or companies described in this article.

Corresponding author: Assia A. Stepanian, MD, Center for Women's Care and Reproductive Surgery, 1140 Hammond Drive, Suite F-6230, Atlanta, GA 30328.

E-mail: [cwcassia@mindspring.com](mailto:cwcassia@mindspring.com)

Submitted August 14, 2007. Accepted for publication November 21, 2007.

Available at [www.sciencedirect.com](http://www.sciencedirect.com) and [www.jmig.org](http://www.jmig.org)

1553-4650/\$ -see front matter © 2008 AAGL. All rights reserved.

doi:10.1016/j.jmig.2007.11.006

One of the first descriptions of sacral colpopexy, using an intervening graft between the vagina and the sacrum, was described in 1962 [1]. Sacral colpopexy is considered one of the most effective operations for treatment of vaginal vault prolapse [2]. In an attempt to minimize morbidity and maintain high cure rates, the laparoscopic approach to this procedure was first described in 1994 to 1995 [3–5]. Published anatomic apical cure rates for sacral colpopexy performed via laparotomy range between 78% to 100% [6], and via laparoscopy the anatomic cure rate is quoted as 90% to 100% [3,7,8]. Despite its high cure rate, sacral colpopexy can have concerning postoperative complications.

One of the most common postoperative complications is mesh extrusion through the vaginal epithelium. Mesh erosion/extrusion usually occurs in the first couple of years, whereas infection is noted soon after surgery. Delayed complications, however, have been described [9,10]. A comprehensive review on abdominal sacral colpopexy reported an overall mesh erosion rate of 3.4% [6]. It was suggested that the procedure should not be performed at the time of hysterectomy in an attempt to reduce bacterial contamination of the prosthetic material [11]. Reports have compared the incidence of mesh erosion in abdominal sacral colpopexy with and without concomitant hysterectomy [12–16]. The results of these studies are not consistent. Three studies suggest an association between hysterectomy [12–14] and mesh erosion and the other 2 do not show such an association [15,16]. A comparison has not been made for the incidence of mesh erosion/extrusion in laparoscopic sacral colpopexy with and without concurrent hysterectomy. In fact, one of the retrospective cohort studies excluded patients who underwent a laparoscopic sacral colpopexy, suggesting that the laparoscopic approach would taint the data [15]. The objective of this study was to estimate incidence of mesh-related complications in women undergoing laparoscopic sacral colpopexy with and without simultaneous laparoscopic-assisted vaginal hysterectomy.

## Materials and Methods

### Study Design

After receiving institutional review board approval, a historical cohort analysis of office and hospital records was performed for all patients who underwent laparoscopic sacral colpopexy from January 2003 through January 2007 at our institution. In all, 446 consecutive patients with uterovaginal or vaginal vault prolapse were treated with laparoscopic sacral colpopexy in conjunction with other laparoscopic and/or vaginal procedures. Data were collected in the form of chart reviews and patient questionnaires. A total of 10 patients with mesh of types other than Y-shaped polypropylene mesh, 11 patients with no follow-up information, and 2 patients with inconsistent data were excluded, as were 21 patients with laparoscopic sacral colpopexy without hysterectomy. A total of 402 remaining patients were enrolled.

Two groups of patients were formed: (1) those receiving concurrent hysterectomy ( $n = 130$ ); and (2) those with a history of hysterectomy ( $n = 272$ ). Patient demographics, history, mesh erosion/extrusion rates, and mesh-related complications were analyzed. Median length of follow-up was 12 months (range: 1–54 months).

### Statistical Analysis

A sample size calculation was performed using 2-sided  $\chi^2$  test with power selected at .80 ( $\beta = .20$ ) and  $\alpha = .05$ . Mesh erosion/extrusion rate was selected as the primary outcome. For power analysis we selected a study [12] that used the same type of mesh in both previous and concurrent hysterectomy groups and stated that one (0.8%) of 121 patients in a previous hysterectomy group and 3 (13.6%) of 22 patients in a concurrent total abdominal hysterectomy (TAH) group developed mesh erosion through the vaginal mucosa, revealing a statistically significant difference between 2 groups. Applying the  $\chi^2$  statistic to compare mesh erosion/extrusion rate between previous and concurrent hysterectomy groups in patients undergoing sacral colpopexy, 70 patients were needed in each group to achieve a confidence level of 95% (2-sided  $\alpha = .05$ ) and a power of 80% ( $\beta = .20$ ).

The 2 study groups were compared using Fisher exact test for proportions and Student's  $t$  test for means. Any  $p$  values less than .05 were considered indicative of statistical significance. Fisher exact 95% CIs were calculated for proportions. To estimate the number of patients in our study needed to achieve the power to detect a statistically significant difference for each complication studied we used a 2-sided Fisher exact test,  $\alpha = .05$ , and equal numbers per group (nQuery Advisor software Version 4.0; Boston, MA). Kaplan-Meier survival analysis was used to assess time to mesh-related complication; the 2 study groups were compared using the log rank test. All analyses were conducted using statistical software (SAS, Version 9; SAS Institute, Cary, NC).

### Surgical Technique

All patients received 1 dose of antibiotic preoperatively. The procedure was performed using 4 trocars in the following locations: 10-mm trocar in the inferior border of the umbilicus; 10-mm trocar at approximately the level of the umbilicus in the left midclavicular line; 5-mm trocar suprapubically in the midline; and another 5-mm trocar at the level of the umbilicus at the right midclavicular line. Each patient was placed in dorsal lithotomy position and carbon dioxide was insufflated to an intraabdominal pressure of 10 mm Hg. The small bowel was mobilized out of the cul-de-sac and placed into the right upper quadrant. After the completion of the laparoscopic aspect of laparoscopic-assisted vaginal hysterectomy (if required), closure of the vaginal cuff was performed via a vaginal approach. Inter-



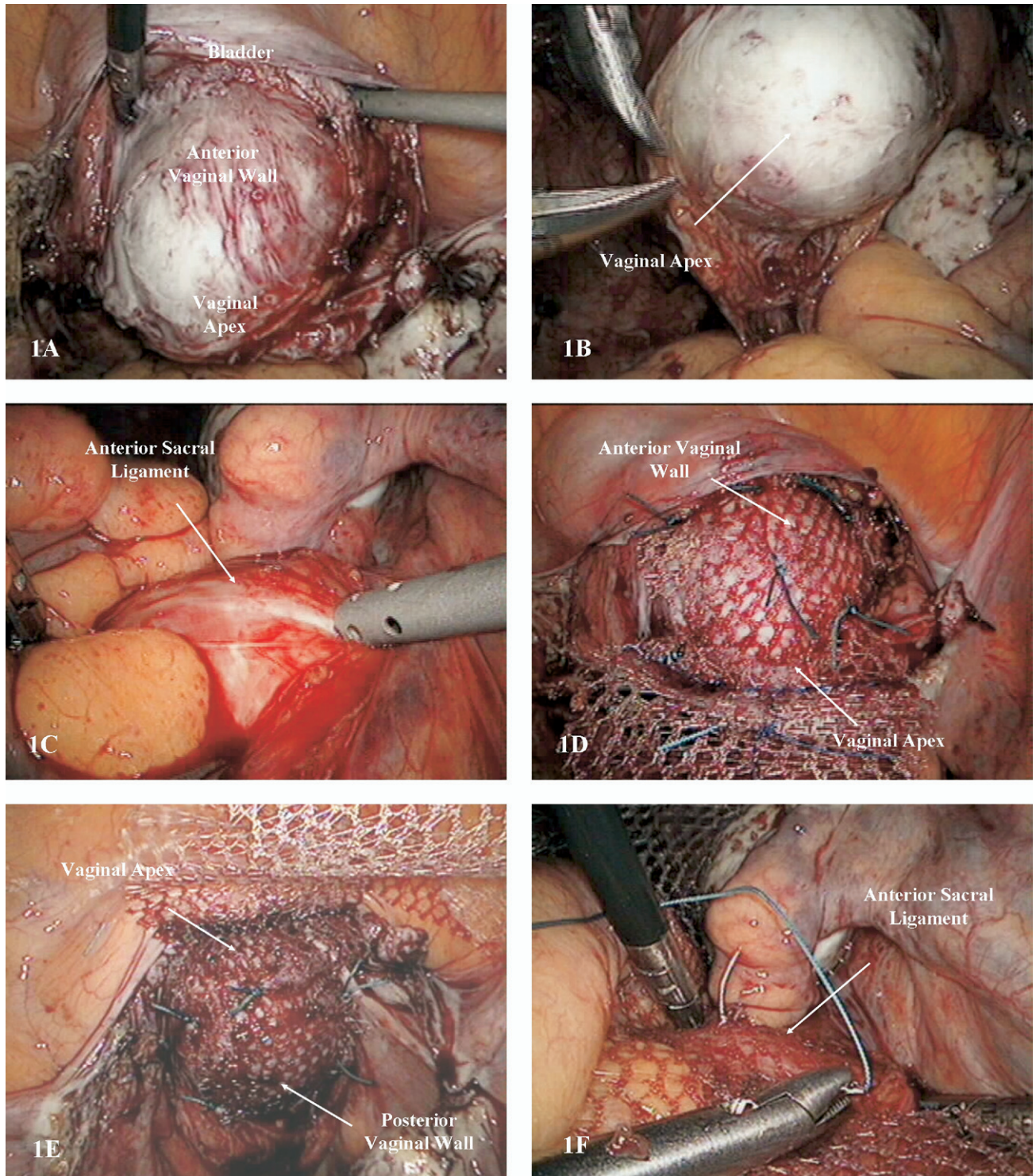


Fig. 1. Steps of laparoscopic sacral colpopexy: anterior (A) and posterior (B) dissection of peritoneum overlying vaginal vault; exposure of anterior ligament of sacrum (C); fixation of anterior and posterior leafs of mesh to anterior (D) and posterior (E) aspects of vaginal cuff, respectively; fixation of mesh to anterior ligament of sacrum (F).

rupted figure-of-eight stitches of 0-polyglactin suture were used to close the cuff.

A vaginal probe was used to elevate the vaginal apex, and the peritoneum overlying the vault was dissected anteriorly exposing the pubocervical fascia (Fig. 1A).

Posterior dissection was performed to delineate the apex of the rectovaginal fascia (Fig. 1B). If a large enterocele was encountered, it was resected to prevent suturing of the mesh to the excessive vaginal epithelium. The peritoneum over the sacral promontory was incised longitudinally.

Table 1  
Demographics

Variable	Concomitant hysterectomy n = 130	H/o hysterectomy n = 272	Fisher's exact, p
Age, y, mean $\pm$ SD (95% CI)	55.2 $\pm$ 13.9 (52.8–57.6)	59.5 $\pm$ 10.1 (58.3–60.7)	.002
Weight, lb, mean $\pm$ SD (95% CI)	148.2 $\pm$ 28.4 (143.3–153.1)	151.3 $\pm$ 26.7 (148.1–154.5)	.32
Largest birth weight, g, mean $\pm$ SD (95% CI)	3704 $\pm$ 520 (3614–3794)	3666 $\pm$ 528 (3603–3729)	.53
Patients with largest birth weight < 4000 g	30.4% (34/112)	28.4% (63/222)	.70
Gravidity median (range)	3 (0–10)	3 (0–8)	.94
Parity median (range)	2 (0–9)	2 (0–6)	.79
Race, No. (%)			
Caucasian	17 (93.6)	239 (96.8)	<.001
African American	7 (5.6)	4 (1.6)	
Other	1 (0.8)	4 (1.6)	
Estrogen users, No. (%)	35 (26.9)	120 (44.1)	.001
Menopausal status, No. (%)			
Premenopausal	27 (25.5)	22 (9.0)	<.001
Perimenopausal	7 (6.6)	6 (2.5)	
Postmenopausal	72 (67.9)	216 (88.5)	

H/o = History of.

dinally (Fig. 1C), and the peritoneal incision was extended into the cul-de-sac. The anterior ligament of the sacral promontory was exposed through blunt dissection. A 15-  $\times$  3- to 4-cm polypropylene mesh fashioned in a Y shape was used to secure the pubocervical fascia anteriorly and the rectovaginal fascia posteriorly. The anterior leaf of the mesh was routinely secured to the proximal 4 to 5 cm of the vaginal cuff using 6 interrupted stitches of nonabsorbable suture, 2-0 polyester (Fig. 1D). The posterior leaf of the mesh was routinely secured using 6 to 8 interrupted stitches of the same suture (Fig. 1E). The long arm of the Y-shaped mesh graft was then secured to the anterior ligament of the sacrum using either 2 or 3 interrupted nonabsorbable sutures or titanium tacks (Fig. 1F). Polypropylene mesh was extraperitonealized using absorbable suture of 2-0 poliglecaprone along the previously made peritoneal incision. Additional surgical repairs such as enterocele repair, retropubic urethropexy, slings, paravaginal repairs, and posterior repairs were performed in most cases. Cystoscopy was performed in all cases to confirm ureteral patency and bladder integrity. All patients received a 1-week course of antibiotics postoperatively. Estrogen vaginal cream was used postoperatively in all patients with preoperatively noted vaginal mucosal atrophy.

## Results

Records were reviewed for 402 patients meeting study criteria. In all, 130 patients with concurrent hysterectomy and 272 patients with a previous hysterectomy were followed up postoperatively for 1 to 54 months. The demo-

graphic data, including age, ethnicity, gravidity and parity, weight, largest birth weight inclusive of deliveries via cesarean section, and estrogen-containing preparation use, are shown in Table 1. Data comparing patients' surgical history in each group are provided in Table 2. Estimation of the incidence of mesh-related complications including mesh erosion/extrusion was the primary focus of this study.

## Demographics

No statistically significant differences existed between the groups in patients' weight, largest birth weight, gravidity, parity, and steroid drug use. Patients in previous hysterectomy group were older (59.5  $\pm$  10.1 [95% CI 58.3–60.7] vs 55.2  $\pm$  13.9 [95% CI 52.8–57.6] years,  $p = .002$ ), used more estrogen supplementation (44.1% [120 of 272] vs 26.9% [35 of 130],  $p = .001$ ), and were more often postmenopausal (216 of 272 vs 72 of 130,  $p < .001$ ). Although ethnicity was not statistically different in the 2 groups, the prevalence of a Caucasian population in this study was evident, with 93.6% Caucasian patients in the concomitant hysterectomy group and 96.8% Caucasian patients in the history of hysterectomy group.

## Histories

Table 2 shows significant differences in number of pelvic and abdominal procedures, with higher rate observed in previous hysterectomy group. In comparison with 13 (10%) patients in concurrent hysterectomy group, 237 (87%) patients in previous hysterectomy group had undergone pelvic floor reconstructive procedures before sacral colopexy.



Table 2  
Surgical history

Procedure	Concomitant hysterectomy n = 130 (%)	Previous hysterectomy n = 272 (%)	Fisher's exact, p
A&P repair	1 (0.8)	31 (11.4)	<.001
SCP	0 (0)	3 (1.1)	.55
PVR	2 (1.5)	16 (5.9)	.07
AR	0 (0.9)	19 (7.0)	<.001
PR	5 (3.8)	33 (12.1)	.006
Enterocoele repair	1 (0.8)	17 (6.3)	.010
Urethral support	2 (1.5)	55 (20.2)	<.001
	Sling-2	Sling-33 Burch-12 Raz-6 MMK-6	
Bladder support	2 (1.5)	39 (14.3)	<.001
Surgery for VVP or UVP	0 (0)	27 (9.9)	<.001
Abdominoplasty	3 (2.3)	25 (9.2)	.011
Cesarean section	6 (4.6)	11 (4.0)	.60
Hernia repair	5 (3.8)	22 (8.1)	.14
Adhesiolysis	3 (2.3)	20 (7.4)	.019
Appendectomy	21 (16.2)	54 (19.9)	.41
Other abdominal surgeries	5 (3.8)	11 (4.0)	1.00
Total No. of pelvic floor procedures	13 (10)	237 (87.1)	<.001

A&P = anterior and posterior; AR = anterior repair; MMK-6 = Marshall-Marchetti-Krantz operation; PR = posterior repair; PVR = paravaginal repair; SCP = sacral colpopexy; UVP = uterovaginal prolapse; VVP = vaginal vault prolapse.

### Types of Mesh Used

Only cases in which macroporous polypropylene Y mesh was used were included in the study: 171 patients had laparoscopic sacral colpopexy performed with IntePro (American Medical Systems, Minnetonka, MN) and 231 with Gynemesh (Gynecare Inc., Menlo Park, CA). No statistically significant differences were established between the study groups on the basis of types of meshes used,  $p = .67$ .

### Complications

As shown in Table 3, no statistically significant differences existed between 2 groups in rates of mesh erosion/extrusion through vaginal epithelium, mesh-associated infection, mesh reaction, pain at the apex requiring treatment, and mesh revision or removal.

Risk of mesh erosion/extrusion in the prior hysterectomy group was 0.7% (2/272) as compared with 2.3% (3/130) in patients with concurrent hysterectomy,  $p = .18$ . The overall mesh erosion/extrusion rate was 1.2% (95% CI 0.5%–2.7%). Each patient with mesh erosion/extrusion was initially treated with a 6-week course of estrogen and antibiotic vaginal creams. None of these patients was cured with this therapy, uniformly requiring surgical treatment, and subsequently leading to an overall excision of exposed mesh rate of 1.2% (95% CI 0.5%–2.7%). The rate of excision did not differ between the 2 compared groups, and equaled 0.7% and 2.3% in previous hysterectomy and concomitant hys-

Table 3  
Complications

Complication	Overall complication rate (n = 402) No. rate (95% CI)	Concomitant hysterectomy (n = 130) No. (rate)	Previous hysterectomy (n = 272) No. (rate)	Fisher's exact, p
Mesh extrusion	5 1.2 (0.5–2.7)	3 (2.3)	2 (0.7)	.18
Excision of exposed mesh	5 1.2 (0.5–2.7)	3 (2.3)	2 (0.7)	.18
Pain at apex	5 1.2 (0.5–2.7)	1 (0.8)	4 (1.5)	1.00
Reoperation for pain at apex	4 1.0 (0.3–2.4)	1 (0.8)	3 (1.1)	.60
Infection	1 0.3 (0.01–1.2)	1 (0.8)	0	.32
Questionable mesh reaction	1 0.3 (0.01–1.2)	0	1 (0.4)	1.00
Reoperation for mesh-related complications, total	11 2.7 (1.4–4.7)	5 (3.9)	6 (2.2)	.27
Bleeding/hematoma	3 0.75 (0.15–2.17)	1 (0.8)	2 (0.7)	1.00
Ileus/SBO	9 2.24 (1.03–4.21)	3 (2.3)	6 (2.2)	.72
Injury to bladder	6 1.49 (0.55–3.22)	0	6 (2.2)	.18
Injury to bowel	3 0.75 (0.15–2.17)	0	3 (1.1)	.55
Injury to ureter	1 0.25 (0.01–1.38)	0	1 (0.4)	1.00

SBO = small bowel obstruction.

Table 4  
Number of patients needed to achieve power in current study

Complication	Overall complication rate (n = 402) No. rate (95% CI)	Power of current study (%)	Sample size (No. of patients) needed/group
Mesh extrusion	5 1.2 (0.5–2.7)	48	975
Excision of exposed mesh	5 1.2 (0.5–2.7)	48	975
Pain at apex	5 1.2 (0.5–2.7)	1	3850
Reoperation for pain at apex	4 1.0 (0.3–2.4)	1	17 000
Infection	1 0.3 (0.01–1.2)	2	1030
Questionable mesh reaction	1 0.3 (0.01–1.2)	1	2340
Reoperation, total	11 2.7 (1.4, 4.7)	9	1700

terectomy groups, respectively ( $p = .18$ ). No cases of mesh erosion through organs and tissues other than vaginal mucosa were observed in this study.

Our study did not suggest an association between concomitant procedures and the location of the exposed mesh. In 5 patients with identified mesh extrusion, exposed mesh was noted in 2 patients at the apex itself, in 2 patients within 2.5 cm from the apex, and in 1 patient at 0.5 to 1 cm posterior to the apex. Three of these patients had concurrent paravaginal repair and posterior repair, 1 patient had enterocele repair, and 4 had urethral support procedures. Two patients had had pelvic floor reconstructive procedures performed before sacral colpopexy, and 2 different patients had abdominoplasty.

No statistically significant differences were established between 2 groups in pain at the vaginal apex. Four of 272 patients in a previous hysterectomy group and 1 of 130 patients in a concurrent hysterectomy group (1.5% and 0.8%, respectively) ( $p = 1.0$ ) developed pain at the apex with the overall rate of 1.2% (95% CI 0.5%–2.7%). Mesh was entirely removed in 4 of 5 patients with pain at the apex, establishing an overall rate of 1% (95% CI 0.3%–2.4%), with a 1.1% rate of removal in prior hysterectomy group and a 0.8% rate in concomitant hysterectomy group,  $p = .60$ .

Cuff abscess occurred in 1 patient with concomitant hysterectomy, and in no patients in the other group, establishing the overall infection rate of 0.3% (95% CI 0.01%–1.2%),  $p = .32$ . A questionable mesh reaction was observed in one patient in a previous hysterectomy group, and in no other groups, leading to overall mesh reaction rate of 0.3% (95% CI 0.01%–1.2%), with no statistically significant differences between the 2 studied groups,  $p = 1.00$ . Both of the above patients had their mesh removed.

Total reoperation rate for mesh-associated complications, including excision of exposed mesh and removal of mesh, was 2.2% in prior hysterectomy group and 3.9% in patients with concurrent hysterectomy (6 of 272 and 5 of

130 patients, respectively). This established a  $p$  value of .27 and revealed absence of statistically significant difference.

### Nonmesh-Related Complications

As seen in Table 3, preoperative complications observed in the current study include hematoma formation 0.75% (95% CI 0.15%–2.17%); ileus/small bowel obstruction 2.24% (95% CI 1.03%–4.21%); and injuries to bladder 1.49% (95% CI 0.55%–3.22%), ureters 0.25% (95% CI 0.01%–1.38%), and small bowel 0.75% (95% CI 0.15%–2.17%). In all 3 cases of reoperation for small bowel obstruction, mesh was not located in proximity to the obstructed area. In fact, in 1 case, the area of obstruction was in a side of the abdomen contralateral to mesh location.

### Estimation of Sample Size Needed to Achieve Power

As shown in Table 4, because the power of this study for mesh extrusion is 48%, the number of patients needed to achieve a statistically significant difference in mesh extrusion alone equaled 975 for each group of patients. This required enrollment of at least 1950 patients.

### Length of Follow-up

The length of follow-up was variable, with the range of 1 to 54 months and median of 12 months. No statistically significant difference existed between the 2 groups with regard to time to mesh-related complications (Fig. 2). At 24 months, the previous hysterectomy group and concomitant hysterectomy group had estimated proportions of 0.967 and 0.935 without mesh-related complications, respectively.

### Discussion

Multiple procedures for uterovaginal and vaginal vault prolapse have been successfully performed laparoscopically. Recently conducted comparative cohort analysis indicated the comparable aspects of laparoscopic and open

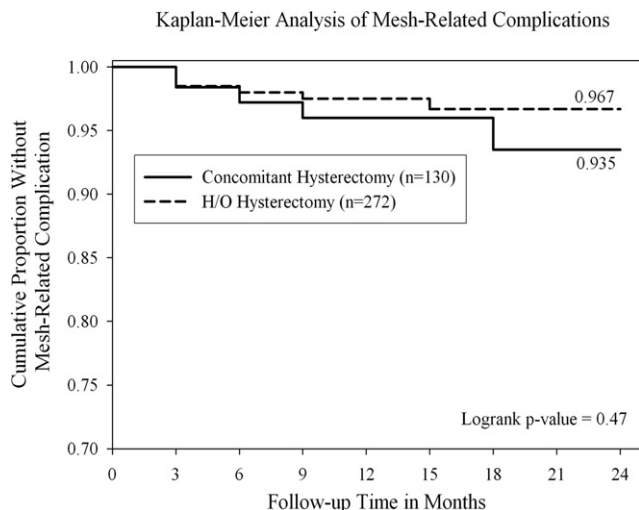


Fig. 2. Kaplan-Meier survival analysis and log rank test. No statistically significant difference between 2 groups existed with regard to time to mesh-related complications. At 24 months, history of (H/O) and concomitant hysterectomy groups had estimated proportions of 0.967 and 0.935 without mesh-related complications, respectively.

abdominal approaches to sacral colpopexy with respect to clinical outcomes and safety whereas the laparoscopic approach offers the benefits of minimally invasive surgery [17]. In addition to providing minimally invasive access to the peritoneal cavity [18], the laparoscopic approach to sacral colpopexy contributes to superior visualization of the operative field because of magnification of the image, concentration of the light at the site of surgical action, and visualization of the tissue and instruments at selected distances [5,19].

An essential role in success and safety of sacral colpopexy is attributed to the selection of an appropriate graft material. Since the beginning of this study, all of our patients have been treated with macroporous, monofilament, soft polypropylene meshes, classified as type I [20]. Larger pores of these mesh materials, greater than 75 nm, allow macrophage and leukocyte migration and, thus, reduce infection [21,22]. Presence of large pores also improves flexibility of the mesh [23,24] and promotes tissue ingrowths and collagen deposition [25]. Polypropylene material has the lowest stiffness compared with other prosthesis and leads to the development of well-organized, fibrous, mature connective tissue [26].

Mesh erosion/extrusion is a complication that is seen in between 0.8% and 19% of cases of abdominal sacral colpopexy during the follow-up time of 0 to 74 months [16,22] and between 0.9% and 8% of cases of laparoscopic sacral colpopexy at 13.5 months to 5 years of follow-up [8,17,27]. Patients with mesh erosion/extrusion most often have new-onset blood-tinged vaginal discharge and nonspecific pelvic pain usually occurring between 4 and 20 months [22]. Other described sequelae of mesh extrusion include sinus tract formation [28], abscess [29], and sacral osteomyelitis [29].

The suggested causal factors for mesh extrusion or exposure are synthetic meshes of types other than type I [21], atrophic vaginal mucosa, placement of the sutures at often devascularized and thin vaginal apex [9,30], and placement of mesh under tension [31]. The last factor results in exposure of the posterior aspect of the vaginal apex to abdominal pressure and leads to subsequent mesh exposure in this region. In an attempt to prevent vaginal mesh erosion/extrusion, we: (1) avoided placing sutures at the vaginal cuff itself; (2) improved vaginal mucosal status by administering vaginal estrogen cream; (3) used perioperative antibiotics; (4) chose macroporous soft polypropylene mesh; (5) reduced significant enterocele and avoided it when placing mesh fixation sutures; and (6) placed this mesh in a tension-free pattern to maintain natural orientation of the vagina [18,31].

A special place in the literature is devoted to studies addressing the effect of concomitant hysterectomy on risk of mesh erosion/extrusion. Our investigation of the current literature did not identify studies on laparoscopic sacral colpopexy in which mesh-associated complications were compared between previous and concomitant hysterectomy groups. One study noted a statistically significant ( $p = .04$ ), 7-fold increased risk of mesh erosion in patients who underwent abdominal sacral colpopexy with concomitant total abdominal hysterectomy in comparison with women who had previous hysterectomy and concomitant supracervical hysterectomy. Range of follow-up in this study was 0.3 to 63.3 months [14]. Another study stratified patients according to the type of concurrent hysterectomy to evaluate the effect of supracervical hysterectomy on the risk of mesh erosion. That study also revealed a higher risk of mesh erosion in the concomitant total abdominal hysterectomy group (10.5%) as compared with a 3.6% mesh erosion rate in patients with concurrent supracervical hysterectomy, but the study lacked the power to achieve statistical significance [32].

A low, 0.8% overall rate of vaginal mesh erosion was documented in a study at 0 to 74 months of follow-up [16]. They explained such a high success of prevention of mesh extrusion by repairing the vaginal cuff in 2 layers. No incidence of mesh erosion was noted in a concurrent abdominal hysterectomy group. Mesh erosion was reported, however, in 1 patient with previous hysterectomy. Based on retrospective analysis of 363 cases of laparoscopic sacral colpopexy with average follow-up duration of 14.6 months, a similarly low overall rate of mesh extrusion (0.9%) was reported. Results were explained by tacking the posterior mesh to the levator ani musculature, avoiding posterior vaginal erosion, by careful dissection of levator ani and vagina, and, finally, by reperitonealization [8].

One study revealed that in women on estrogen therapy hysterectomy was associated with higher risk of mesh erosion [15]. The authors explained this association, however, by the possible presence of vaginal mucosal atrophy as an indication for estrogen use. Review of the records of our patients who developed mesh extrusion indicated that es-

trogenization was adequate in all patients at the time of preoperative evaluation; one patient was using estrogen preoperatively; surgical and postsurgical care was the same in each patient.

Although there are no published reports on success of the conservative management of mesh erosion, transvaginal surgical excision [9,33,34] and transvaginal endoscopic techniques for removal of eroded mesh have been described [33]. Patients in our study responded well to transvaginal excision of an exposed mesh. We excised surrounding mesh granulation tissue, applied downward traction to the exposed mesh, and excised its visible fragment. The surrounding vaginal mucosa and underlying fascia were closed using interrupted stitches of delayed absorbable suture. This procedure was previously described [9,33,34]. Consistent with this study, no recurrence of mesh exposure occurred after the excision of exposed mesh; no removal of the entire mesh was necessary. In addition, previously described complications of treatment of mesh erosion were not observed, including infection, abscess, and sinus tract formation [28].

The median time to diagnosis and treatment of mesh extrusion in our study was 6 months, with a range of 3 weeks to 19 months. Studies involving various types of meshes documented a range of 6 weeks to 72 months as time to mesh exposure after sacral colpopexy [9,16,33]. A study [14] involved 121 patients with polypropylene mesh and revealed that 3 of 4 patients developed mesh extrusion/erosion during the first 5 to 10 months of follow-up. One additional extrusion was diagnosed at 24 months after surgery. Although we have probably seen most cases that are to develop mesh extrusion in our study, potentially longer follow-up may be necessary to assess mesh-related complications with higher accuracy of detection.

## Conclusion

The risks of mesh-related complications associated with laparoscopic sacral colpopexy were low and equal to about 1% for mesh extrusions, infection, reaction, and apical pain. We believe that low risk of mesh-related complications is the result of use of macroporous soft knitted polypropylene mesh and strict adherence to surgical techniques indicated to decrease the risk of mesh exposure and other mesh-related complications.

No statistically significant differences in mesh-related complication rates between previous hysterectomy and concurrent hysterectomy groups were noted, and we could not prove that laparoscopic hysterectomy that is concurrent to laparoscopic sacral colpopexy is associated with an increased risk of mesh-associated complications. Based on our data, 975 patients were required in each group to achieve power to detect a statistically significant difference in complication rates in this study if primary outcome continues to be mesh erosion/extrusion.

Although we believe in the protective effect of vaginal estrogenization in the prevention of mesh extrusion/erosion,

all patients with mesh extrusion/erosion had adequate estrogenization. This suggests that adequate vaginal estrogenization status does not preclude mesh-related complications.

The excision of the exposed mesh was shown to be an optimal treatment for mesh extrusions that resulted from laparoscopic sacral colpopexy.

## Acknowledgment

We would like to thank Dawn Blackhurst, PhD, for her statistical analysis of this study.

## References

1. Lane FE. Repair of posthysterectomy vaginal-vault prolapse. *Obstet Gynecol.* 1962;20:72–77.
2. Gadonneix P, Ercoli A, Scambia G, Villet R. The use of laparoscopic sacrocolpopexy in the management of pelvic organ prolapse. *Curr Opin Obstet Gynecol.* 2006;17:376–380.
3. Nezhat CH, Nezhat F, Nezhat C. Laparoscopic sacral colpopexy for vaginal vault prolapse. *Obstet Gynecol.* 1994;84:885–888.
4. Dorsey JH, Cundiff G. Laparoscopic procedures for incontinence and prolapse. *Curr Opin Obstet Gynecol.* 1994;6:223–227.
5. Lyons TL. Minimally invasive treatment of urinary stress incontinence and laparoscopically directed repair of pelvic floor defects. *Clin Obstet Gynecol.* 1995;38:380–391.
6. Nygaard IE, McCreery R, Brubaker L, Connolly A, Cundiff G, Weber AM, et al. Abdominal sacrocolpopexy: a comprehensive review. *Obstet Gynecol.* 2004;104:805–823.
7. Antiphon P, Elard S, Benyoussef A, Fofana M, Yiou R, Gettman M, et al. Laparoscopic promontory sacral colpopexy: is the posterior, recto-vaginal, mesh mandatory? *Eur Urol.* 2004;45:655–661.
8. Rozet F, Mandron E, Arroyo C, Andrews H, Cathelineau X, Mombet A, et al. Laparoscopic sacral colpopexy approach for genito-urinary prolapse; experience with 363 cases. *Eur Urol.* 2005;47:230–236.
9. Kohli N, Walsh PM, Roat TW, Karra MM. Mesh erosion after abdominal sacrocolpopexy. *Obstet Gynecol.* 1998;92:999–1004.
10. Weidner AC, Cundiff GW, Harris RL, Addison WA. Sacral osteomyelitis: an unusual complication of abdominal sacral colpopexy. *Obstet Gynecol.* 1997;90:689–691.
11. Imparato E, Spesi G, Rovetta E, Presti M. Surgical management and prevention of vaginal vault prolapse. *Surg Gynecol Obstet.* 1992;175:233–237.
12. Thompson PK, Pugmire JE, Santi-Haghepykar H. Abdominal sacrocolpopexy utilizing Gore-Tex in genital prolapse. *J Pelvic Med Surg.* 2004;10:311–317.
13. Culligan PJ, Murphy M, Blackwell L, Hammons G, Graham C, Heit MH. Long-term success of abdominal sacral colpopexy using synthetic mesh. *Am J Obstet Gynecol.* 2002;187:1473–1482.
14. Bensinger G, Lind L, Lesser M, Guess M, Winkler H. Abdominal sacral suspensions: analysis of complications using permanent mesh. *Am J Obstet Gynecol.* 2005;193:2094–2098.
15. Wu JM, Wells EC, Hundley AF, Connolly AM, Williams KS, Visco AG. Mesh erosion in abdominal sacral colpopexy with and without concomitant hysterectomy. *Am J Obstet Gynecol.* 2006;192:1418–1422.
16. Brizzolara S, Pillai-Allen A. Risk of mesh erosion with sacral colpopexy and concurrent hysterectomy. *Obstet Gynecol.* 2003;102:306–310.
17. Paraiso MF, Walters MD, Rackley RR, Melek S, Hugney C. Laparoscopic and abdominal sacral colpopexies: a comparative cohort study. *Am J Obstet Gynecol.* 2005;192:1752–1758.



18. Miklos JR, Moore RD, Kohli N. Laparoscopic surgery for pelvic support defects. *Curr Opin Obstet Gynecol.* 2002;14:387–395.
19. Wattiez A, Mashiach R, Donoso M. Laparoscopic repair of vaginal vault prolapse. *Curr Opin Obstet Gynecol.* 2003;15:315–319.
20. Deval B, Haab F. What's new in prolapse surgery? *Curr Opin Urol.* 2003;13:315–323.
21. Birch C, Fynes MM. The role of synthetic and biological prosthesis in reconstructive pelvic floor surgery. *Curr Opin Obstet Gynecol.* 2002;14:527–595.
22. Govier FE, Kobashi KC, Kozlowski PM, Kuznetsov DD, Begley SJ, McGonigle KF, et al. High complication rate identified in sacrocolpopexy patients attributed to silicone mesh. *J Urol.* 2005;65:1099–1103.
23. Costantini E, Lombi R, Micheli C, Parziani S, Porena M. Colposacropepy with Gore-Tex mesh in marked vaginal and uterovaginal prolapse. *Eur Urol.* 1998;34:111–117.
24. Davila GW, Drutz H, Deprest J. Clinical implications of the biology of grafts: conclusions of the 2005 IUGA grafts roundtable. *Int Urogynecol J.* 2006;17:S51–S55.
25. Davila GW, Moore RD, Giudice TP, Erickson TB. Innovations in the treatment of vaginal prolapse. *OBG Manage.* 2006;18:1. Available at [www.obgmanagement.com](http://www.obgmanagement.com).
26. Boulangeir L, Boukerrou M, Lambaudie E, Defossez A, Cosson M. Tissue integration and tolerance to meshes used in gynecologic surgery: an experimental study. *Eur J Obstet Gynecol Reprod Biol.* 2006;125:103–108.
27. Ross JW, Preston M. Laparoscopic sacrocolpopexy for severe vaginal vault prolapse: five-year outcome. *J Minim Invasive Gynecol.* 2005;12:221–226.
28. Hart SR, Weiser EB. Abdominal sacral colpopexy mesh erosion resulting in a sinus tract formation and sacral abscess. *Obstet Gynecol.* 2004;103:1037–1040.
29. Taylor GB, Moore RD, Miklos JR. Osteomyelitis secondary to sacral colpopexy mesh erosion requiring laminectomy. *Obstet Gynecol.* 2006;107:475–477.
30. Richardson AC. The anatomic defects in rectocele and enterocele. *J Pelvic Surg.* 1995;1:214–221.
31. Hunt WG. Abdominal sacral colpopexies complicated by vaginal graft extrusion. *Obstet Gynecol.* 2004;103:1033–1034.
32. Griffis K, Evers M, Terry C, Hale D. Mesh erosion and abdominal sacrocolpopexy; a comparison of total and supracervical hysterectomy. *J Pelvic Med Surg.* 2004;10:S15–S16.
33. Timmons MC, Addison WA. Mesh erosion after abdominal sacral colpopexy. *J Pelvic Surg.* 1997;2:75–80.
34. Mattox TF, Stanford EJ, Varner E. Infected abdominal sacrocolpopexies: diagnosis and treatment. *Int Urogynecol J Pelvic Floor Dysfunct.* 2004;15:319–323.